

# **Study about Efficacy of Dr. Michaels Pharmaceuticals in Psoriasis in Sanatorium of Prof. Novotný in Prague.**

The goal of the study was verification of the efficacy of Dr. Michaels remedies in selected patients suffering from psoriasis.

The comparative tests have monitored status and therapy before dr.Michaels treatment. This fact is described in 10 patients under review.

We have processed 10 cases and delivered a comprehensive evaluation.

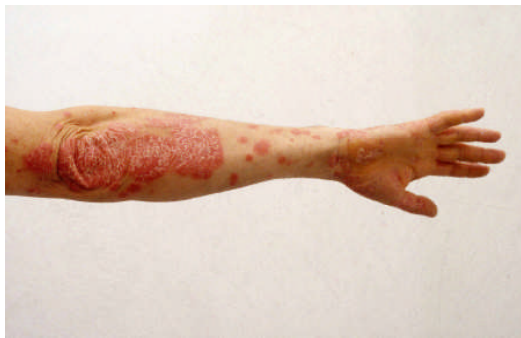## 1st patient

Sex: feminine

Age: 35 years

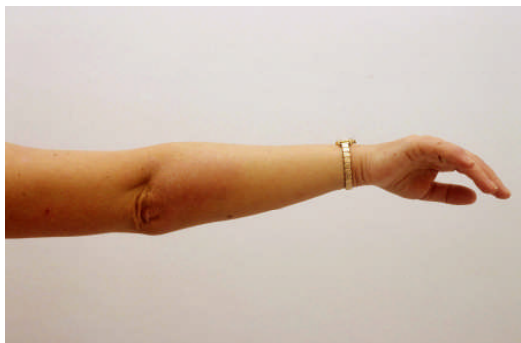Diagnosis: Psoriasis vulgaris chronica typica localisata olecrani. The disease continues for 5 years. The previous local corticoids treatment with low, temporary effect without complete recovery.

Figure No. 1.



before treatment

Figure No.2.



5 weeks after treatment

Consolidation 100%. The consolidation lasts in the meanwhile for 3 months. The patient is further monitored. Consumption 1 set. Course without complications. Internal finding and laboratory tests normal. Histological image after treatment completely normalized.

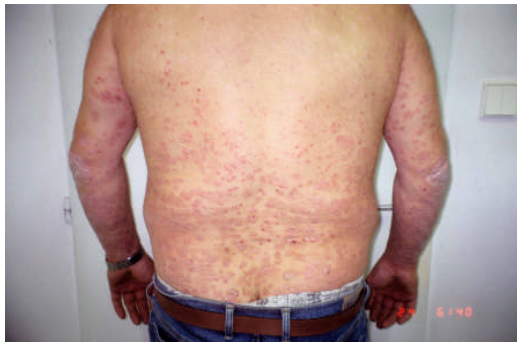## 2nd patient

Sex: masculine

Age: 42 years

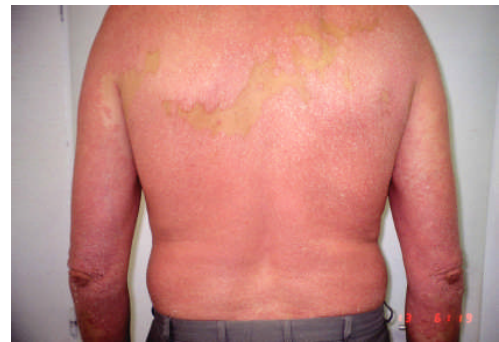Diagnosis: Psoriasis chronica disseminata corporis et arthropathica. The disease continues for 11 years. The present extent on the trunk continues for 5 years. Previous external therapy by pix, derivates vitamins D3, corticoids, UVB solarization and internally methotrexate. Partial results.

Figure No. 3.



before treatment

Figure No.4.



4 weeks after treatment

Consolidation 85%. Lasting mauve areas withdraw of methothrexate. Dr. Michaels therapy continues. Consumption in the meanwhile 3 sets. The articular disorders on hands and feet last. Course without subjective complications. The patient is satisfied, he evaluates the results very positive comparing to the previous therapy. Laboratory finding after one month of treatment: Hepatic tests improved, total bilirubin from 32 mmol/l to 24, ALT from 122 mkat/l to 85 and GMT from 113 mkat/l to 78. Cholesterol 6,2 mmol/l, triacylglycerols 2,4 mmol/l. Otherwise normal. Histological finding: persist slight lymphocytar infiltration in upper corium, slightly augmented capillaries and imperceptible acanthosis.

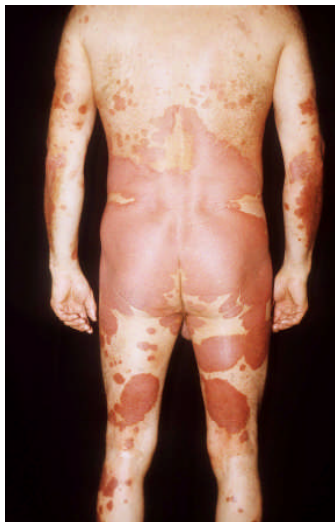### 3rd patient

Sex: masculine

Age: 38 years

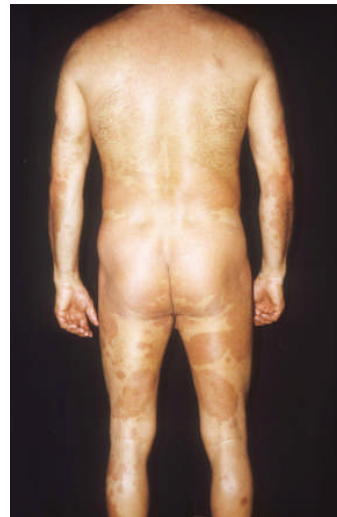Diagnosis: Psoriasis vulgaris chronica disseminata neurogenes. Psoriasis continues for 8 years in total, present status for 2 years. The previous general treatment by cyclosporine A without good effect, locally emollientia. Creatinine level increased to 280 mmol/l, blood pressure 180/90 mm Hg. Because of torpidity applied Dr.Michaels remedies.

Figure No. 5.



before treatment

Figure No.6.



6 weeks after treatment

Consolidation 85%. Therapy continues. In the meanwhile applied 3 sets. Other remedies were not used. Last slight pigmentations. We could evaluate the results of the therapy on 90%. Tolerance good. Laboratory finding: creatinine decreased to 128 mmol/l and blood pressure to 160/75 mm Hg. Otherwise normal. Histological finding: Apart from slight hyperkeratosis normal.

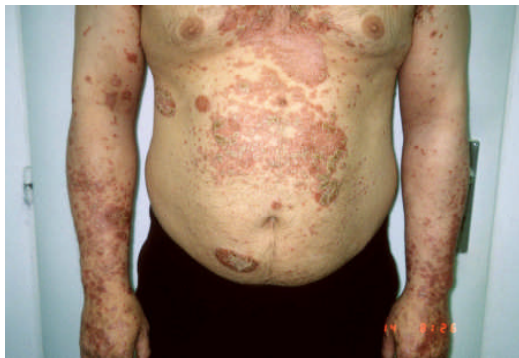## 4th patient

Sex: masculine

Age: 32 years

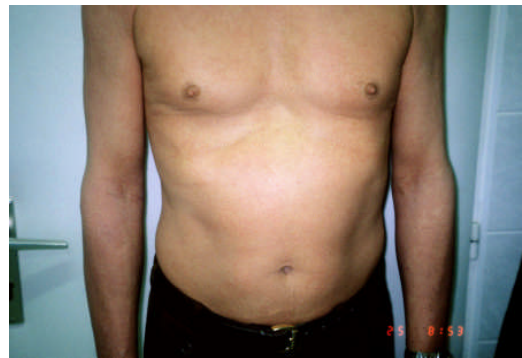Diagnosis: Psoriasis vulgaris chronica disseminata irritativa. Psoriasis continues repeatedly for 8 years, present status for 9 months. It itches. The previous treatment: externally corticoids, dithranol, salicylic acid and urea. Temporary results. UVB solarization without effect.

Figure No. 7.



before treatment

Figure No. 8.



8 weeks after treatment

Consolidation 100%. The patient further monitored. Consumption 3 sets. Other remedies were not used. General clinical status and histological finding after the therapy completely normal.

Laboratory finding: higher level of cholesterol 6,4 mmol/l. At present is the patient on diet. The patient is very satisfied.

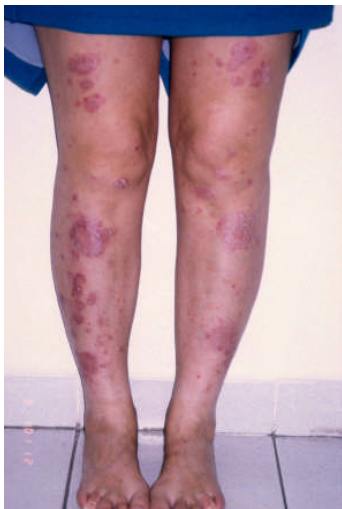
## 5th patient

Sex: feminine

Age: 43 years

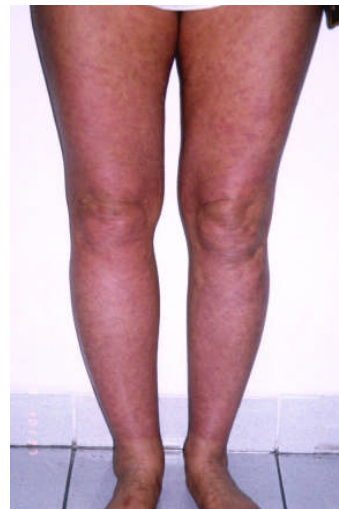Diagnosis: Psoriasis subacuta recidivans cruris. Duration of present relapse 2 months. Itch. The previous treatment by local corticoids without effect.

Figure No. 9.



before treatment

Figure No. 10.



4 weeks after treatment

Consolidation 95%. The treatment continues. Consumption 1 set. Lasts slight erythema, it does not itch. Tolerance good. Internal, laboratory and histological finding within the bound of normal. Absolute satisfaction compared to previous therapy.

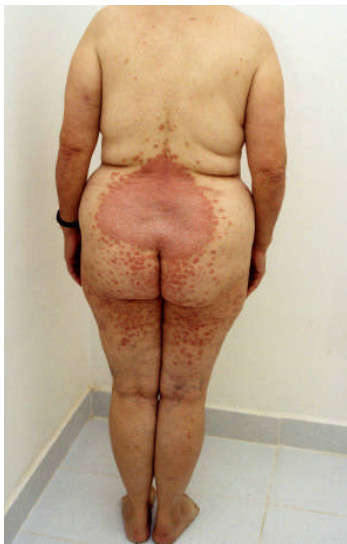## 6th patient

Sex: feminine

Age: 51 years

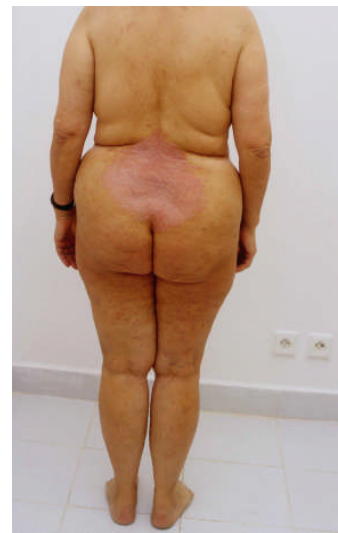Diagnosis: Psoriasis vulgaris chronica localisata regionis sacralis. Diabetes mellitus. Hypercholesterolemia. Obesity. Duration repeatedly 3 years. Previous treatment: by local derivates of vitamin D3 without result. Internally insulin and diet.

Figure No. 11.



before treatment

Figure No. 12.



4 weeks after treatment

Consolidation in the meanwhile 55%. The focus smaller, the erythema lasts. The therapy continues. Consumption 1 set. Lasts higher glycemia 7,4 mmol/l and hypercholesterolemia 8,2 mmol/l. Blood pressure 150/80 mm Hg. Histological finding: Lasts inflammatory infiltration and acanthosis with parakeratosis. The patient indicates as a side effect a temporary burning in the first days after the application of Dr. Michaels remedies. Further diet.

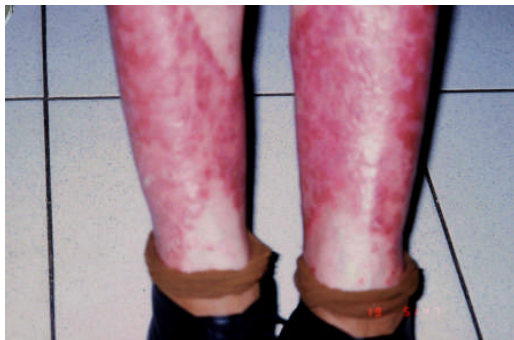## 7th patient

Sex: feminine

Age: 47 years

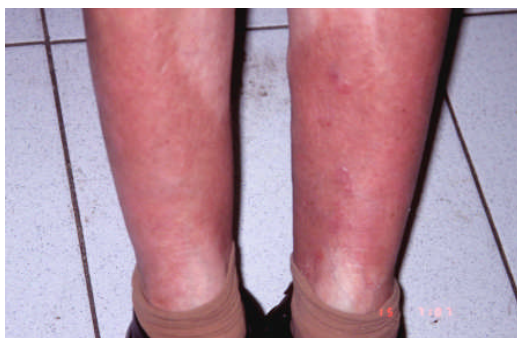Diagnosis: Psoriasis subchronica cruris. Stress. Solar allergy. It itches. Psoriasis repeats for about 12 years. Present status lasts for 8 months. Previous treatment: by local corticoids and emollientia. With partial result.

Figure No. 13.



before treatment

Figure No. 14.



4 weeks after treatment

We could evaluate the treatment on 75%. The therapy continues. Consumption in the meanwhile 1 set. Course without complications. Laboratory without pathological finding. Histological finding: Lasts slight inflammatory infiltration, augmented capillaries in corium and slight acanthosis

The patient evaluates the therapy as better than the previous therapy by corticoids.



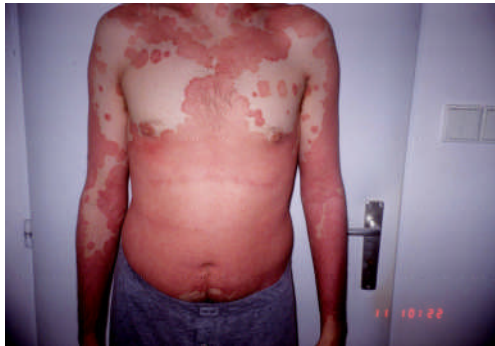## 8th patient

Sex: masculine

Age: 38 years

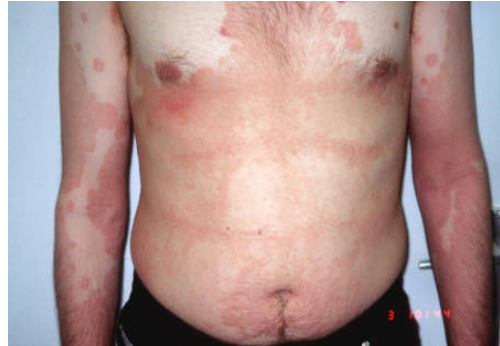Diagnosis: Psoriasis chronica generalisata. Repeated tonsillitis during infancy. Marked family disposition. Present status lasts for 2 years, previously less manifestations. Previous treatment by internal retinoids (Neotigason), balneophototherapy, locally emollientia. The status remains unchanged.

Figure No. 15.



before treatment

Figure No. 16.



4 weeks after treatment

The treatment continues successfully. The status improved in the meanwhile on 60%. Persist mainly pigment areas, sporadic slight erythema. The therapy is well tolerated. The patient consumed in the meanwhile 4 sets. Internally without problems, laboratory idem. Histological finding: Lasts slight hyperkeratosis. Recommended tonsillectomy.

## Summary Evaluation

From the indications we select above all chronic forms of psoriasis. Acute disseminations could be for Dr. Michaels remedies risky. We do not have experience with psoriatic erythrodermia and pustular psoriasis, both Zumbusch's and Barber's type.

We evaluate the results of therapy by Dr. Michaels remedies on average on 90% namely not only in 10 cases monitored in the study but in additional 65 cases treated in our clinic by these remedies. We take for important the selection of appropriate chronic indications. We have compared the results with other local methods. External corticoids give positive results on average in 72%, analogs of vitamin D3 on average in 79% and phototherapy in 83%.

The tolerance of the therapy is very good. We note as side effects temporary burning in the beginning of the therapy in about 8% of cases under review. We have not observed any internal side effects. Instead of that the previous laboratory tests have normalized, mainly hepatic and renal functions, for example after the withdrawal of methotrexat, cyclosporine A and retinoid. We monitored in our study laboratory values of blood picture, FW, glucose, cholesterol, triacylglyceroles, bilirubin, GMT, ALT, AST, creatinine, uric acid and urea in blood. We have not seen any impairment.

Interesting is the persistence of the remissions. We monitor a lull period in 65 cases during at least one year and relapses of small extent occurred just in 30% of monitored cases. While the relapses show up in patients suffering from psoriasis treated by local corticoids on average in 1 to 2 months and in patients treated internally by methotrexat, cyclosporine A and retinoids and newly by biological preparations roughly in 3 months. The repetition of the treatment by Dr. Michaels preparations appears in the meanwhile equally successful while after other methods the success, when we repeat the same therapy, decreases.

We consider as an important moment of the therapy a consistent instruction of the patients how to apply the preparations. In the same time we recommend reducing diet in obese patients and prevention of stress. We recommend intensive phototherapy in an interval of approx. 3 weeks after the recovery. It is possible to apply a common solarization 3 hours after the therapy with a sunscreen protection.

We recommend to retain clearing gel on the moistened skin longer, 10 to 15 minutes. We have even observed that the disposal of solitary gel is efficient in the same time or it is possible to combine it with other methods.

The satisfaction of the patients is exceptional. Dr. Michaels remedies are evaluated by the patients as much better comparing to the other previous therapy. The beginning of the effects comes already in 3 to 5 weeks.

The histological findings eventuate in normalization.

Explanation of Mechanism of Effects of Dr. Michaels Preparations:

In my opinion it is the combination of more components. I regard as essential the superficial action effect of fruit acids as in the cosmetic peeling. The plant extracts act anti-inflammatory. This is the impulse for the healing process, which arises from the basal cells of the skin. I consider as important other components as zinc oxide, evening primrose oil and tee tree oil. Lauryl sulphate helps the penetration into the epidermis. Psychotherapy and confidence in a new efficient remedy are important in the same time.

The 21st, 22nd and 23rd figures show the persistence of mauve and slight pigment focuses after the ending of the therapy by Dr. Michaels remedies. These manifestations eventually spontaneously relent. We do not see this fact so often in other therapeutical approaches.

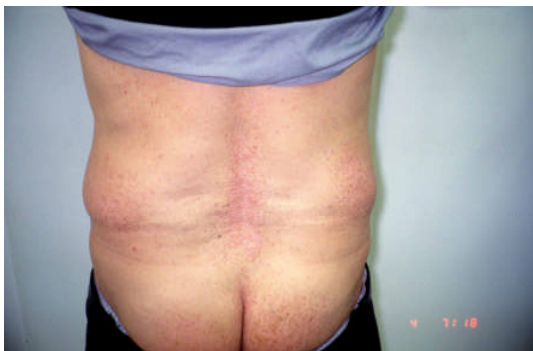
Figure No. 21.

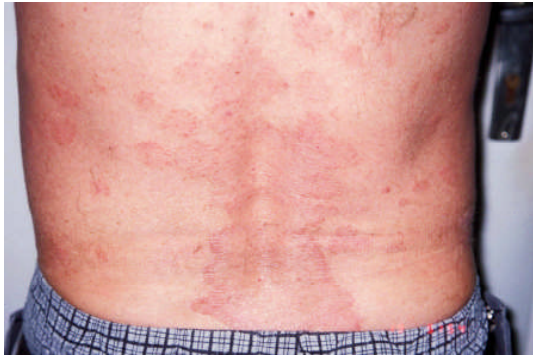

Figure No. 22.

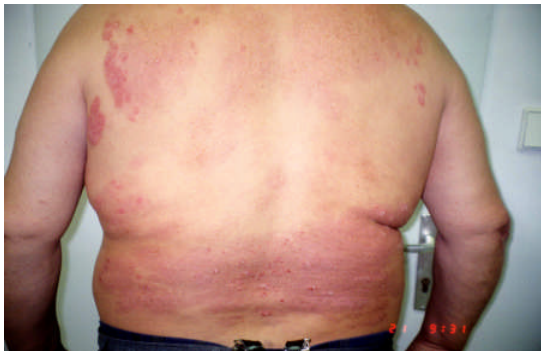

Figure No. 23.



## CONCLUSION

In conclusion, Dr. Michaels product family can be used successfully for the treatment of mild to moderately – severe chronic plaque psoriasis. There were no major side effects associated with the treatment, neither clinically nor from laboratory findings. In fact, laboratory tests for the liver and kidneys showed marked improvement after the treatment compared to the results before the treatment started. 75% of the patients treated achieved total resolution of their skin lesions while 15% show significant improvement (resolution of at least 75% of the lesions). There were minor side effects of itching and burning in 10% of the patients.

The results of the trial show that the products are very effective in the treatment of chronic plaque psoriasis, with a 90% success rate.



In Prague, 5.12. 2006

Prof. František Novotný, MD., PhD.  
PRO SANUM Ltd., Sanatorium of Prof. Novotný  
Štěpánská 24  
110 00 PRAGUE 1  
CZECH REPUBLIC